

Relationship Between Retinal Glial Cell Activation in Glaucoma and Vascular Dysregulation

Matthias C. Grieshaber, MD, Selim Orgul, MD, Andreas Schoetzau, MS, and Josef Flammer, MD

Purpose: To investigate the possible relationship between presumed activated retinal astrocytes and Müller cells (ARAM) and primary vascular dysregulation (PVD) in patients with primary open-angle glaucoma (POAG).

Patients and Methods: One hundred eighty-six eyes of 93 patients with POAG were included in the study. Presumed ARAM was defined as patchy, discrete glittering but transparent changes of the retina. The diagnosis of PVD was based on both the patient's history and an abnormal circulatory behavior. Frequency tables were used to describe categorical variables, and differences were compared by means of χ^2 test. A generalized linear mixed model was applied to determine the influence of vascular dysregulation, mean visual defect, and age on ARAM.

Results: ARAM was found to be bilateral in 26.8% of patients (50 eyes), and unilateral in 11.8% (11 eyes). Patient's mean age was 68.6 (SD \pm 8.1) years in the group with ARAM and 65.6 (SD \pm 13.6) years in the group without ($P = 0.56$). In the generalized linear mixed model, ARAM was significantly associated with vascular dysregulation [odds ratios (OR): 4.4, confidence intervals (CI): 1.7-11.3, $P = 0.002$] but not with greater age (OR: 1.1 per decade of years, 0.7-1.6, $P = 0.48$) and eye side (OR: 1.1, CI: 0.8-1.6, $P = 0.52$). An increase of mean visual defect of 5.5 dB doubled the risk for ARAM (OR: 2.0; CI: 1.5-2.7, $P < 0.001$).

Conclusions: Presumed retinal glial cell activation in POAG is clearly related to vascular dysregulation and to some extent to the stage of glaucomatous damage.

Key Words: astrocytes, glaucoma, glial cells, intraretinal gliosis, Müller cells, neuronal tissue remodeling

(*J Glaucoma* 2007;16:215-219)

Glaucomatous optic neuropathy, the most common optic neuropathy, is characterized by progressive loss of retinal ganglion cells and cupping of the optic nerve head associated with visual-field defects. Both increased intraocular pressure (IOP) and disturbed ocular blood flow have been implicated in the pathogenesis of glaucoma.¹ Traditionally, clinical morphologic diagnosis has been directed toward the excavation of the optic nerve head and retinal nerve fiber layers. Additional signs of glaucomatous change are optic disc hemorrhages² and peripapillary atrophy.³ Recently, activation of retinal glial cells has also been implicated in glaucoma.^{4,5}

Astrocytes and Müller cells are 2 major types of macroglial cells in the retina.^{6,7} Whereas the Müller cells span the entire depth, from the vitreal border to the photoreceptor layer, the astrocytes are concentrated in the superficial layer of the retina. Both types of macroglial cells occur in the entire retina with the exception of the nonvascular foveal area.⁸ The number of cells declines toward to the periphery. The extensions of the astrocytes surround both the retinal ganglion cells axons and the blood vessels. The most extensive contact is, however, between Müller cells and ganglion cell bodies and dendrites. One of the main functions of glial cells is to preserve integrity of neuronal tissue.

Glial cell activation is a typical response to injuries of central nervous system. The retina is part of the central nervous system and therefore reacts in a similar way. The activation of glial cells, well demonstrated by increased glial fibrillary acidic protein staining, has been described in the retina in response to light damage and to hypoxic or mechanical stress.⁹⁻¹² Retinal astrocytes and Müller cells become also activated in glaucoma. This includes a change of both the function and the morphology of these cells.¹³⁻¹⁵

The presumed clinical appearance of activated retinal astrocytes and Müller cells (termed presumed ARAM) in glaucoma patients are patchy, discrete glittering but transparent alterations of the retina.^{4,5} Examples are given in Figures 1 to 3. Presumed ARAM vary in size and distribution, but are predominantly located in the paracentral retina sparing the fovea and the papillo-macular bundle. In addition, they preferentially lie in vicinity of the major retinal vessels. In contrast to epiretinal membrane, presumed ARAM do not cause retinal contraction, tortuosity of the retinal vessels, pseudoforamina in the macula or retinal edema.^{4,5} Therefore, ARAM do not lead to visual disturbances

Received for publication April 25, 2006; accepted October 26, 2006.
From the Department of Ophthalmology, University Hospital Basel, Basel, Switzerland.

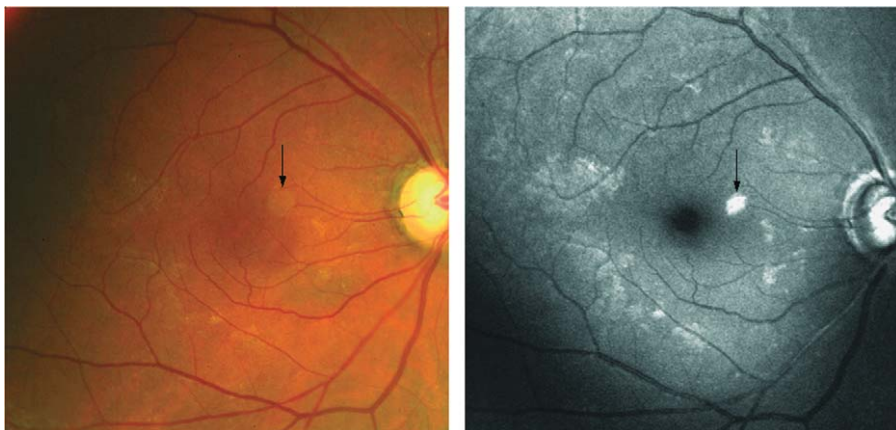
Financial disclosure: None of the authors have a proprietary or financial interest in any material or method mentioned.

Financial support: Neither public nor private financial support was received for this study.

Reprints: Josef Flammer, MD, Department of Ophthalmology, University Hospital Basel, Mittlere Strasse 91, PO Box, CH 4031 Basel, Switzerland (e-mail: josef.flammer@uhbs.ch).

Copyright © 2007 by Lippincott Williams & Wilkins

FIGURE 1. Color and red-free photography of a patient with presumed ARAM, which are clearly visualized. Note the patchy distribution in the macula sparing the fovea. Presumed ARAM do not correspond to the pattern of the retinal nerve fiber bundle defect. Arrows indicate light-reflex from the camera.



like reduced visual acuity or metamorphopsia. For documentation, ARAM can best be visualized with a scanning laser fundus camera using a green argon laser, whereas they are barely discernable on color fundus photography^{4,5} (Figs. 1 to 3). Figure 4 shows a fundus color and red-free photograph of a glaucoma patient without ARAM as a control.

Presumed ARAM has been suggested to occur more often in patients with primary vascular dysregulation (PVD) than without PVD.^{4,5} PVD, including the propensity to react by vasospasm to various stimuli such as coldness and emotional stress, has been suggested to represent a potential risk factor for glaucomatous damage.^{1,16} PVD does also involve ocular circulation.¹⁷⁻¹⁹ This study tested the hypothesis of a relationship between ARAM and PVD in patients with POAG.

PATIENTS AND METHODS

Glaucoma patients were prospectively enrolled from the Glaucoma Service, Department of Ophthalmology, University Hospital of Basel, Switzerland, between January and July 2005. The duration of the study period was determined by the time to include at least 35 POAG patients with ARAM in at least 1 eye that fulfilled the

inclusion criteria. The cut-off number was set at 35 before starting the recruitment, based on the number of independent variables needed. The selection criteria for POAG were according to the guidelines of the European Glaucoma Society. Eyes of patients with narrow or closed iridocorneal angle, evidence for any secondary glaucoma, pigmentary dispersion, pseudoexfoliation, a history of trauma, of chronic or recurrent inflammatory eye disease (eg, scleritis, uveitis), of intraocular surgery, ocular trauma, any form of retinal disease (eg, age-related macular degeneration, high myopia) that could result in retinal pathology or visual field defects or patients with a history of chronic systemic disease, including diabetes mellitus, systemic hypertension, or occlusive vascular disorders, were excluded from this study.

All patients qualified for this study had a complete ophthalmologic examination. The iris was dilated with phenylephrine and tropicamide for indirect funduscopy. Particular attention was paid to the retina for the presence of ARAM and to the optic nerve head for glaucomatous damage. The decision whether ARAM was present or not was done by 2 independent observers which were masked to the diagnosis of PVD and to the visual fields. The groups were determined after ARAM was assigned.

FIGURE 2. Color and red-free photography of another patient with mild forming of presumed ARAM in the right eye. Note the characteristic location in the vicinity of retinal vessels. Arrows indicate light-reflex from the camera.

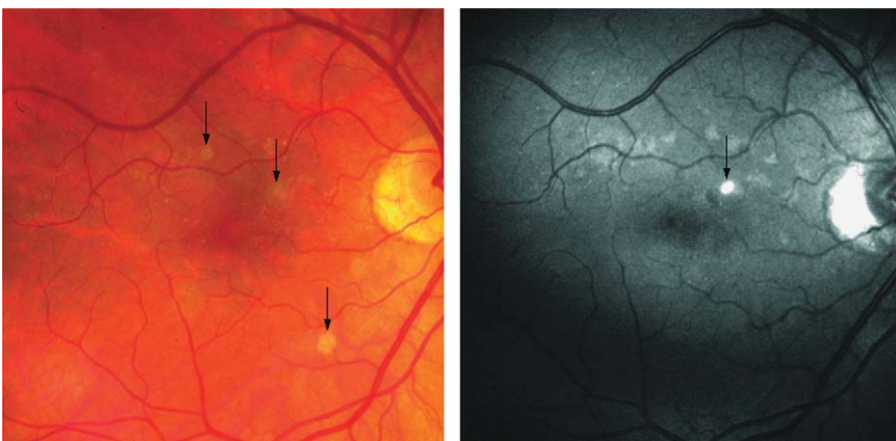
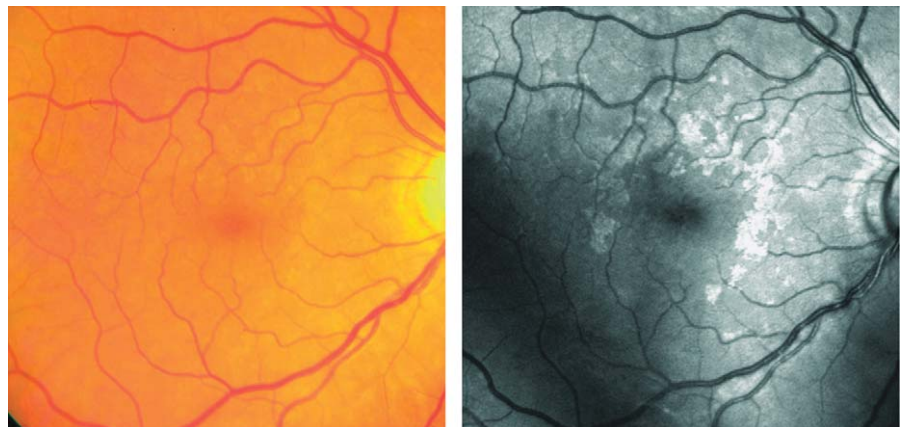


FIGURE 3. Another example of a patient with presumed ARAM, which are barely discernible on color photography, but clearly visible on red-free image. Note the typically patchy, relatively sharp demarcated appearance of ARAM and the gap in the fovea.



Laser Scanning Imaging of the Retina

Retinal structures are difficult to visualize and to photograph because the retina is vastly optically transparent. Blue light scatters more than red light. This is the reason why the retinal nerve fiber layer can be visualized to some extent with red-free light. The extensions of the astrocytes form a fine meshwork, which becomes denser and irregular as these astrocytes are activated,¹⁴ and in addition, the size and number of glial cells increase, as the neural cell damage advances. These changes in turn may increase the light scattering and with scanning laser fundus camera (Heidelberg Retina Angiograph, Heidelberg, Germany; wavelength 488 nm), increased reflection and light scattering from the retina can be detected.

Visual Fields Examination

Visual fields were performed with automated static threshold perimetry Octopus 101 program G1 (Haag-Streit, Berne, Switzerland) and the mean visual defect (MD) was defined as mean defect.^{20,21} All patients had typical glaucomatous disc and visual field damage. A cluster of 3 points (except the rim points) in at least 1 hemifield reduced by 5 dB or greater, and including at least 1 point reduced by 10 dB or greater; or 3 adjacent points on the nasal horizontal meridian that differed by

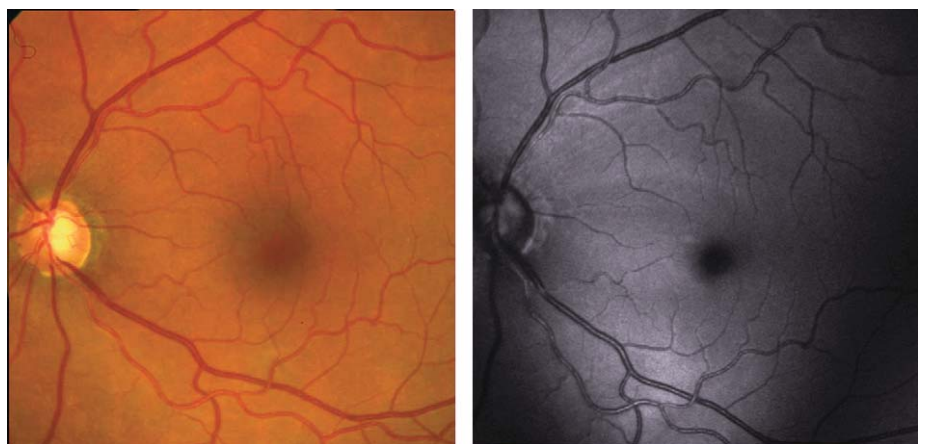
5 dB or greater from their mirror points on the opposite side of the meridian were required for minimal criteria for glaucomatous visual field defects. Patients with poor visual field reliability (false positive or false negative errors exceeding 25%) were not included.

In addition, all patients were evaluated for vascular dysregulation. Patients were defined as having PVD if they had both an unambiguous history of frequent cold hands (answering yes to the questions: “do you have cold hands, even during the summer?” and “do other people tell you that you have cold hands?”) and an abnormal circulatory response to stimuli in at least 1 of the examinations described below. Not included were patients with a positive history for vascular dysregulation but with a normal response in the vascular examination.

Nailfold Capillary Microscopy

Briefly, the nailfold capillary microscopy²² is a microscopic examination of the nailfold capillaries, where a light microscope is coupled to a video monitor. The monitor, in turn, is coupled to a recorder, allowing the observed blood flow to be videotaped for later analysis. The examination is performed in a room with a constant temperature of about 23°C (range 21°C to 25°C). During capillary microscopy, the nailfold area is cooled to –15°C for 60 seconds by rapidly decompressing carbon

FIGURE 4. Color and red-free fundus photography of a glaucoma patient without ARAM.



dioxide. During cooling, the blood in the capillaries sometimes stops flowing. Digital vasospasm is defined if one or more visible capillaries are closed over a mean stoppage time of longer than 12 seconds.

Laser Doppler Flowmetry of the Choroid and Isometric Hand-grip Test

The abnormal response of ocular blood flow was evaluated based on the choroidal vascular reaction to isometric hand grip test as has been previously described in detail.¹⁹ The isometric hand-grip test is a specific, sensitive, reproducible, and noninvasive test of sympathetic function with well-studied reflex pathways.²³ During the isometric hand-grip test, the subfoveal choroidal blood flow was measured by means of the laser Doppler flowmetry.²⁴ In a randomly selected eye of each patient, the choroidal blood flow was measured 3 times—at baseline, during and 3 minutes after hand-grip test. Based on previous findings of healthy subjects²⁵ and glaucoma patients,¹⁹ a decrease in the laser Doppler flowmetry-measured flow during the hand-grip test were considered abnormal, and the limit of relevance was set at a change of 10% or more.

Statistical Methods

Data were extracted from medical records and converted into SPSS for Windows version 13.0 (SPSS, Inc, Chicago, IL). Frequency tables and Fisher exact test were used to study dependencies among categorical variables. The influence of PVD, MD, and age on ARAM was tested using a generalized linear mixed model allowing for a correlated occurrence of ARAM for both eyes. This model for correlated, non-normal distributed outcomes allows inference of factors within an individual patient. We used a computationally efficient penalized quasi-likelihood estimation procedure with a logit link allowing for overdispersion.^{26,27} Computation was performed using the R-software version 2.0.1 (R development core team, 2005). ARAM was the dependent variable, whereas eye side and vascular dysregulation were fixed factors. Age and MD were covariates, and the patient was a random factor. Because female sex is known to be a confounder with vascular dysregulation,¹ the sex was included in the model. Odds ratios (OR) and the corresponding 95% confidence intervals (CI) were estimated for each variable in the model. The level of significance being considered relevant was set at 0.05.

RESULTS

One hundred eighty-six eyes of 93 patients with POAG were included in the study between January and July 2005. Presumed ARAM was found to occur in 61 eyes (32.8%). Presumed ARAM was bilateral in 26.8% of patients (50 eyes), and unilateral in 11.8% (11 eyes). Fifty-seven patients (61.2%) did not have ARAM in any eyes. The IOP (mean $14.97 \pm \text{SD } 4.1$ mm Hg) and central corneal thickness (mean $526.1 \pm \text{SD } 26.8$ μm) in eyes with ARAM was comparable to IOP (mean $15.47 \pm \text{SD } 3.9$ mm Hg) and central corneal thickness ($529.6 \pm \text{SD}$

39.7 μm) in eyes without ARAM ($P = 0.98$ and $P = 0.77$, respectively).

For descriptive statistics of the population, only patients with bilateral presumed ARAM were included. With regard to sex, female patients had in general more often ARAM (18 of 44, 40.9%) than male patients (7 of 38, 18.4%), and also more frequently bilateral ARAM than unilateral (Fisher exact test, $P = 0.03$). The mean age was comparable between patients with bilateral ARAM (68.5 y; $\text{SD} \pm 8.1$) and patients without ARAM (65.5 y; $\text{SD} \pm 13.6$) ($P = 0.56$). The mean MD was 8.5 (range 2.2 to 19.9; $\text{SD} \pm 5.9$) in patients with ARAM and 5.5 (range 2.0 to 17.3; $\text{SD} \pm 4.5$) in patients without ARAM. There were more female (26 of 44) than male patients (11 of 38) having vascular dysregulation (Fisher exact test $P = 0.008$).

In patients with unilateral ARAM, the mean MD of eyes with ARAM was 8.8 (range 2.2 to 21.1; $\text{SD} \pm 5.7$) and of unaffected fellow eyes 4.5 (range 2.1 to 16.6; $\text{SD} \pm 4.3$).

In the generalized linear mixed model, including all 186 eyes, the presence of vascular dysregulation had a significant influence on the presence of ARAM (OR: 4.4, CI: 1.7-11.3, $P = 0.002$); and a greater MD was associated with ARAM (OR: 1.2, CI: 1.1-1.2, $P < 0.001$). To illustrate, an increase in MD of 5.5 dB doubled the risk for ARAM (OR: 2.0; CI: 1.5-2.7). Eye side (OR: 1.1, CI: 0.8-1.6, $P = 0.52$) and patient's age (OR: 1.0, CI: 1.0-1.1, $P = 0.48$) did not correlate with ARAM, and the OR was 1.1 (CI: 0.7-1.6) per decade.

DISCUSSION

In the present study, presumed ARAM was strongly related to PVD and moderately to the stage of POAG quantified by the MD. In contrast, age and eye-side were not related to presumed ARAM.

There is increasing evidence of vascular dysregulation to be involved in the pathogenesis of glaucomatous damage.^{1,28-30} In this study, vascular dysregulation was defined on the basis of the patient's history together with an abnormal response in one of the vascular examinations. This allowed us to clearly differentiate between the patients with from those without vascular dysregulation, although a patient's history alone would have been already conclusive to distinguish between the 2 groups.^{18,19} Patients with vascular dysregulation have the propensity to react inadequately to various stimuli such as coldness and psychologic stress. Blood flow fluctuations owing to vascular dysregulation have been suggested to lead to ischemia-reperfusion injury in the eye.¹ Ischemia-reperfusion events damage mainly neuroretinal cells which are vulnerable to oxygen fluctuations, whereas glial cells are much more resistant.³¹ There is, however, evidence that glial cells become activated by ischemic stress.³² A relationship between the localization of presumed ARAM and the distribution of astrocytes^{33,34} has been suggested.⁵ In addition, activated glial cells also form a fine layer of sheath around the retinal

vessels in human glaucomatous eyes.¹⁴ Other studies have shown a relationship between activated astrocytes with up-regulation of glial fibrillary acidic protein and a change in the blood-brain-barrier.^{35,36} A break-down of the blood-retinal-barrier has indeed been described in glaucoma.³⁷ Under certain condition, such a break-down may even lead to splinter hemorrhages at the optic nerve head.³⁸

It is too early to extrapolate the present findings to the general glaucoma population. Our results may be biased by selective referrals to our institution.

It is tempting to interpret the relationship found between MD and ARAM to be related to the stage of the disease (OR: 1.2). The mean MD was higher in patients with ARAM than in patients without ARAM. However, the fact that a relatively large increase of mean MD (5.5 dB) is necessary to double the risk for ARAM (OR: 2.0) puts the strong statistical relationship into a different clinical perspective. Therefore, further studies are needed before definite conclusions can be drawn in this regard. Interestingly, presumed ARAM in POAG is not associated with age.

In conclusion, glial cell activation was highly associated with PVD and to some extent to the stage of the disease.

REFERENCES

- Flammer J, Orgul S, Costa VP, et al. The impact of ocular blood flow in glaucoma. *Prog Retin Eye Res.* 2002;21:359–393.
- Healey PR, Mitchell P, Smith W, et al. Optic disc hemorrhages in a population with and without signs of glaucoma. *Ophthalmology.* 1998;105:216–223.
- Jonas JB. Clinical implications of peripapillary atrophy in glaucoma. *Curr Opin Ophthalmol.* 2005;16:84–88.
- Graf T, Flammer J, Prunte C, et al. Gliosis-like retinal alterations in glaucoma patients. *J Glaucoma.* 1993;2:257–279.
- Grieshaber MC, Flammer J. Clinical signs of retinal glial cell activation in glaucoma patients. *SE Eur J Ophthalmol.* 2006;1:1–6.
- Newman E. Glia of the retina. In: Ryan SJ, ed. *Retina.* St Louis: Mosby; 2001:89–103.
- Sarthy V, Ripps H. *The Retinal Muller Cell.* New York: Kluwer Academic/Plenum Publishers; 2001.
- Schnitzer J. Astrocytes in the guinea pig, horse, and monkey retina: their occurrence coincides with the presence of blood vessels. *Glia.* 1988;1:74–89.
- de Raad S, Szczesny PJ, Munz K, et al. Light damage in the rat retina: glial fibrillary acidic protein accumulates in Muller cells in correlation with photoreceptor damage. *Ophthalmic Res.* 1996;28:99–107.
- Ekstrom P, Sanyal S, Narfstrom K, et al. Accumulation of glial fibrillary acidic protein in Muller radial glia during retinal degeneration. *Invest Ophthalmol Vis Sci.* 1988;29:1363–1371.
- Yoshida A, Ishiguro S, Tamai M. Expression of glial fibrillary acidic protein in rabbit Muller cells after lensectomy-vitreotomy. *Invest Ophthalmol Vis Sci.* 1993;34:3154–3160.
- Napper GA, Kalloniatis M. Neurochemical changes following postmortem ischemia in the rat retina. *Vis Neurosci.* 1999;16:1169–1180.
- Wang X, Tay SS, Ng YK. An electron microscopic study of neuronal degeneration and glial cell reaction in the retina of glaucomatous rats. *Histol Histopathol.* 2002;17:1043–1052.
- Wang L, Cioffi GA, Cull G, et al. Immunohistologic evidence for retinal glial cell changes in human glaucoma. *Invest Ophthalmol Vis Sci.* 2002;43:1088–1094.
- Lam DY, Kaufman PL, Gabelt BT, et al. Neurochemical correlates of cortical plasticity after unilateral elevated intraocular pressure in a primate model of glaucoma. *Invest Ophthalmol Vis Sci.* 2003;44:2573–2581.
- Flammer J, Haefliger IO, Orgul S, et al. Vascular dysregulation: a principal risk factor for glaucomatous damage? *J Glaucoma.* 1999;8:212–219.
- Gherghel D, Orgul S, Dubler B, et al. Is vascular regulation in the central retinal artery altered in persons with vasospasm? *Arch Ophthalmol.* 1999;117:1359–1362.
- Hasler PW, Orgul S, Gugleta K, et al. Vascular dysregulation in the choroid of subjects with acral vasospasm. *Arch Ophthalmol.* 2002;120:302–307.
- Gugleta K, Orgul S, Hasler PW, et al. Choroidal vascular reaction to hand-grip stress in subjects with vasospasm and its relevance in glaucoma. *Invest Ophthalmol Vis Sci.* 2003;44:1573–1580.
- Flammer J. The concept of visual field indices. *Graefes Arch Clin Exp Ophthalmol.* 1986;24:389–392.
- Flammer J, Jenni A, Bebie H, et al. The Octopus glaucoma G1 program. *Glaucoma.* 1987;9:67–72.
- Gasser P, Flammer J. Blood-cell velocity in the nailfold capillaries of patients with normal-tension and high-tension glaucoma. *Am J Ophthalmol.* 1991;111:585–588.
- Khurana RK, Setty A. The value of the isometric hand-grip test—studies in various autonomic disorders. *Clin Auton Res.* 1996;6:211–218.
- Geiser MH, Riva CE, Diermann U. Measuring choroid blood flow with a new confocal laser Doppler device. *Klin Monatsbl Augenheilkd.* 1999;214:285–287.
- Riva CE, Cranstoun SD, Grunwald JE, et al. Choroidal blood flow in the foveal region of the human ocular fundus. *Invest Ophthalmol Vis Sci.* 1994;35:4273–4281.
- Breslow N, Clayton D. Approximate inference in generalized linear models. *J Am Stat Assoc.* 1993;88:9–25.
- Lin X, Breslow N. Bias correction in generalized linear mixed models with multiple components of dispersion. *J Am Statistical Association.* 1996;91:1007–1016.
- Flammer J, Guthauser U, Mahler F. Do ocular vasospasms help cause low-tension glaucoma? *Doc Ophthalmol Proc Series.* 1987;49:397–399.
- O'Brien C. Vasospasm and glaucoma. *Br J Ophthalmol.* 1998;82:855–856.
- Broadway DC, Drance SM. Glaucoma and vasospasm. *Br J Ophthalmol.* 1998;82:862–870.
- Arai-Gaun S, Katai N, Kikuchi T, et al. Heme oxygenase-1 induced in muller cells plays a protective role in retinal ischemia-reperfusion injury in rats. *Invest Ophthalmol Vis Sci.* 2004;45:4226–4232.
- Osborne NN, Block F, Sontag KH. Reduction of ocular blood flow results in glial fibrillary acidic protein (GFAP) expression in rat retinal Muller cells. *Vis Neurosci.* 1991;7:637–639.
- Schnitzer J. Retinal astrocytes: their restriction to vascularized parts of the mammalian retina. *Neurosci Lett.* 1987;78:29–34.
- Schnitzer J. The development of astrocytes and blood vessels in the postnatal rabbit retina. *J Neurocytol.* 1988;17:433–449.
- Eng LF, Ghirmikar RS, Lee YL. Glial fibrillary acidic protein: GFAP-thirty-one years (1969–2000). *Neurochem Res.* 2000;25:1439–1451.
- Ueda H, Baba T, Terada N, et al. Immunolocalization of dystrobrevin in the astrocytic endfeet and endothelial cells in the rat cerebellum. *Neurosci Lett.* 2000;283:121–124.
- Arend O, Remky A, Plange N, et al. Fluorescein leakage of the optic disc in glaucomatous optic neuropathy. *Graefes Arch Clin Exp Ophthalmol.* 2005;243:659–664.
- Grieshaber MC, Terhorst T, Flammer J. The pathogenesis of optic disc splinter haemorrhages: a new hypothesis. *Acta Ophthalmol Scand.* 2006;84:62–68.